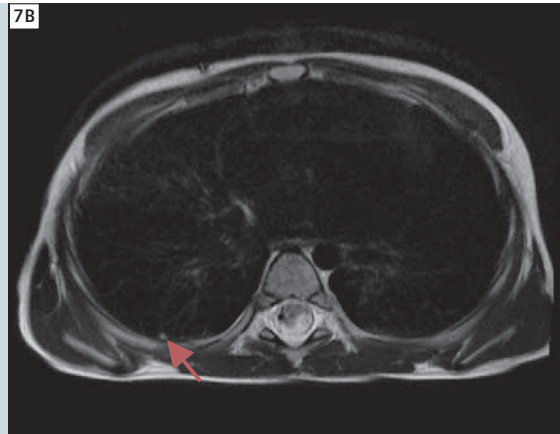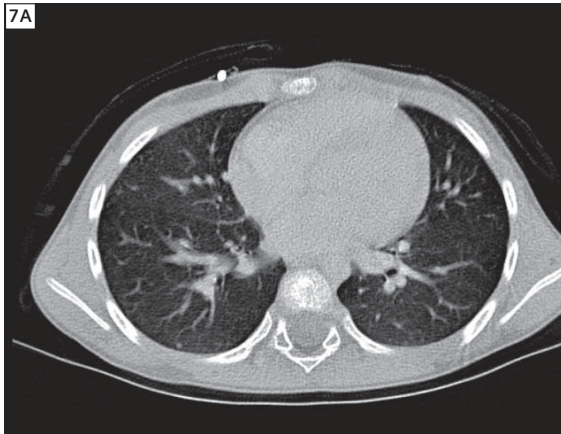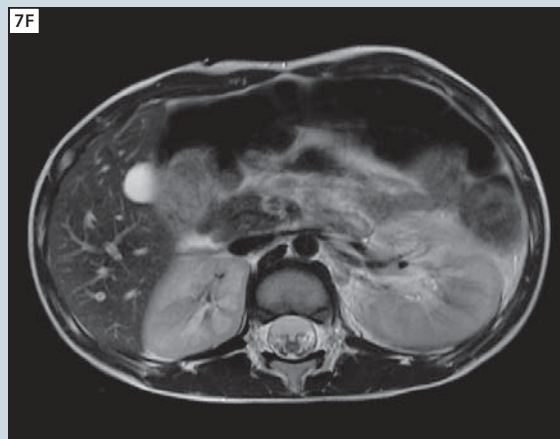
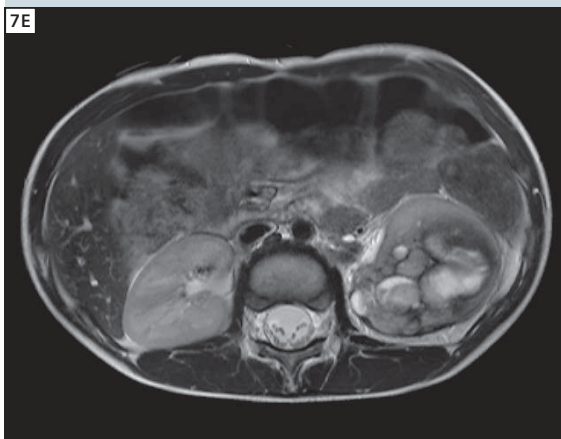
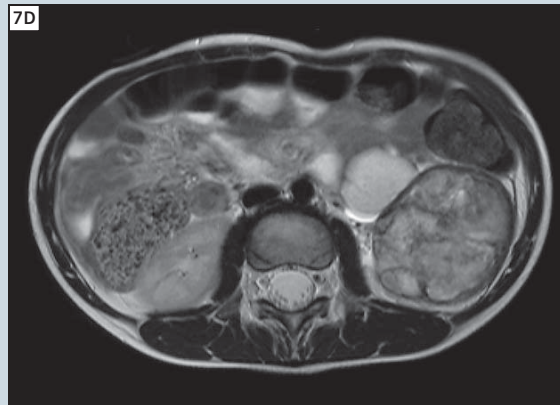
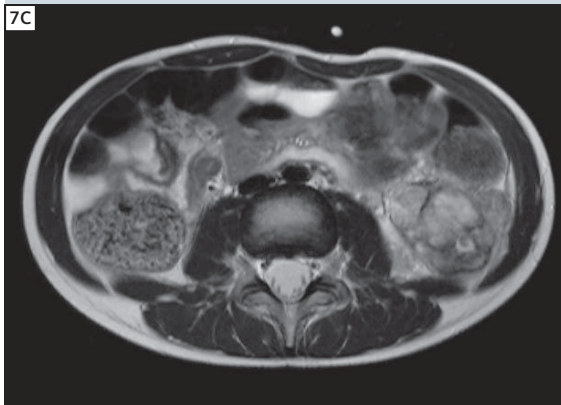


7 Follow-up examination with CT (**A**) still showing a small residual lung metastasis (arrow), which can also be visualized by MRI (**B**). The main tumor is also clearly reduced in its mass after first cycle of chemotherapy (**C-F**) in caudo-cranial sorting.



References

- 1 Kaste, S.C., Dome, J.S., Babyn, P.S., Graf, N.M., Grundy, P., Godzinski, J., Levitt, G.A., Jenkinson, H. 2008 Wilms tumour: Prognostic factors, staging, therapy and late effects *Pediatric Radiology* 38 (1), pp. 2-17.
- 2 Graf, N., Tournade, M.-F., De Kraker, J. 2000 The role of preoperative chemotherapy in the management of Wilms' tumor: The SIOP studies. *Urologic Clinics of North America* 27 (3), pp. 443-454.

Contact

PD Dr. Dr. Günther Schneider
 Dept. of Diagnostic and Interventional
 Radiology
 Saarland University Hospital
 Kirrberger Strasse
 66421 Homburg/Saar
 Germany
dr.guenther.schneider@uks.eu