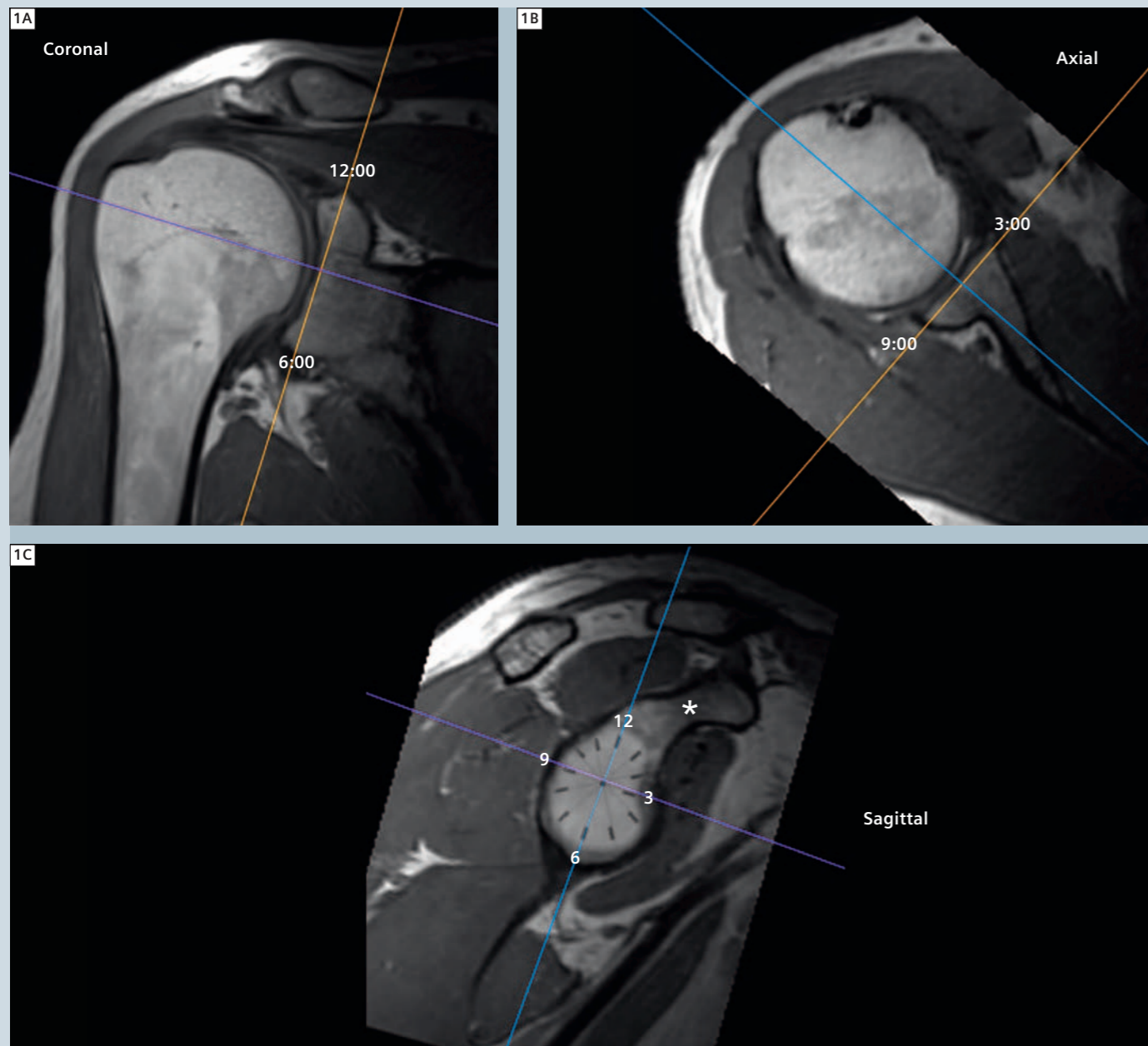


# MRI of the Shoulder: Utilizing the Glenoid Clockface Orientation

Steven D. Needell, M.D.

Boca Radiology Group, P.A., Boca Raton, FL, USA



1 Orientation of coronal (orange line), sagittal (blue line) and axial (purple line) planes using glenoid clockface as reference.

## Background

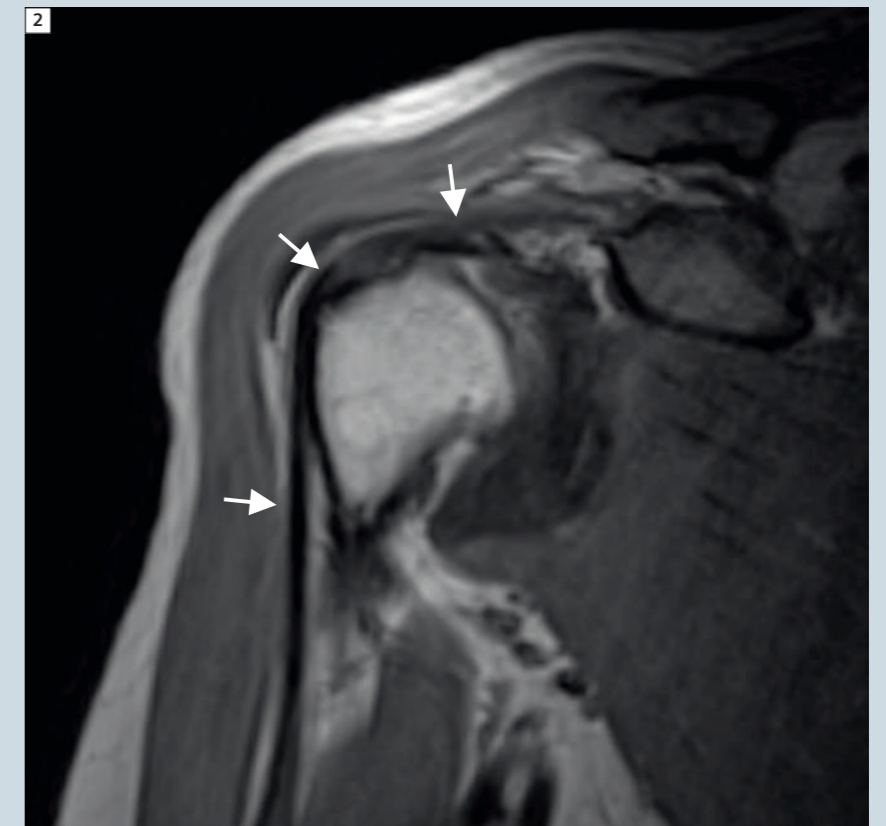Orthopedic surgeons describe the glenoid fossa as the face of a clock, with the longitudinal axis defined by the supraglenoid tubercle marking the 12:00 position and the inferior margin of the glenoid marking the 6:00 position. Orienting the shoulder MRI exam relative to this clockface is ideal because it results in images which consistently correspond with the arthroscopists' perspective and optimally profiles the major anatomic structures of the glenohumeral joint.

## Technique

After obtaining axial scouts, a three plane localizer should be prescribed medial enough to include the coracoid process in the sagittal plane, which is essential to orienting the exam to the glenoid clockface. In the sagittal plane, identify the coracoid process, which projects anterosuperiorly off the neck of the scapula and defines the 1:00 position of the glenoid clockface for a right shoulder and the 11:00 position for a left shoulder. Coronal sequences are prescribed parallel to a line bisecting the 12:00 superior and 6:00 inferior positions of the glenoid fossa on a sagittal image (Fig. 1). Axial sequences are prescribed perpendicular to the coronal plane, and bisect the 3:00 and 6:00 positions (Fig. 1). Sagittal sequences are prescribed perpendicular to the glenoid rim (Fig. 1).

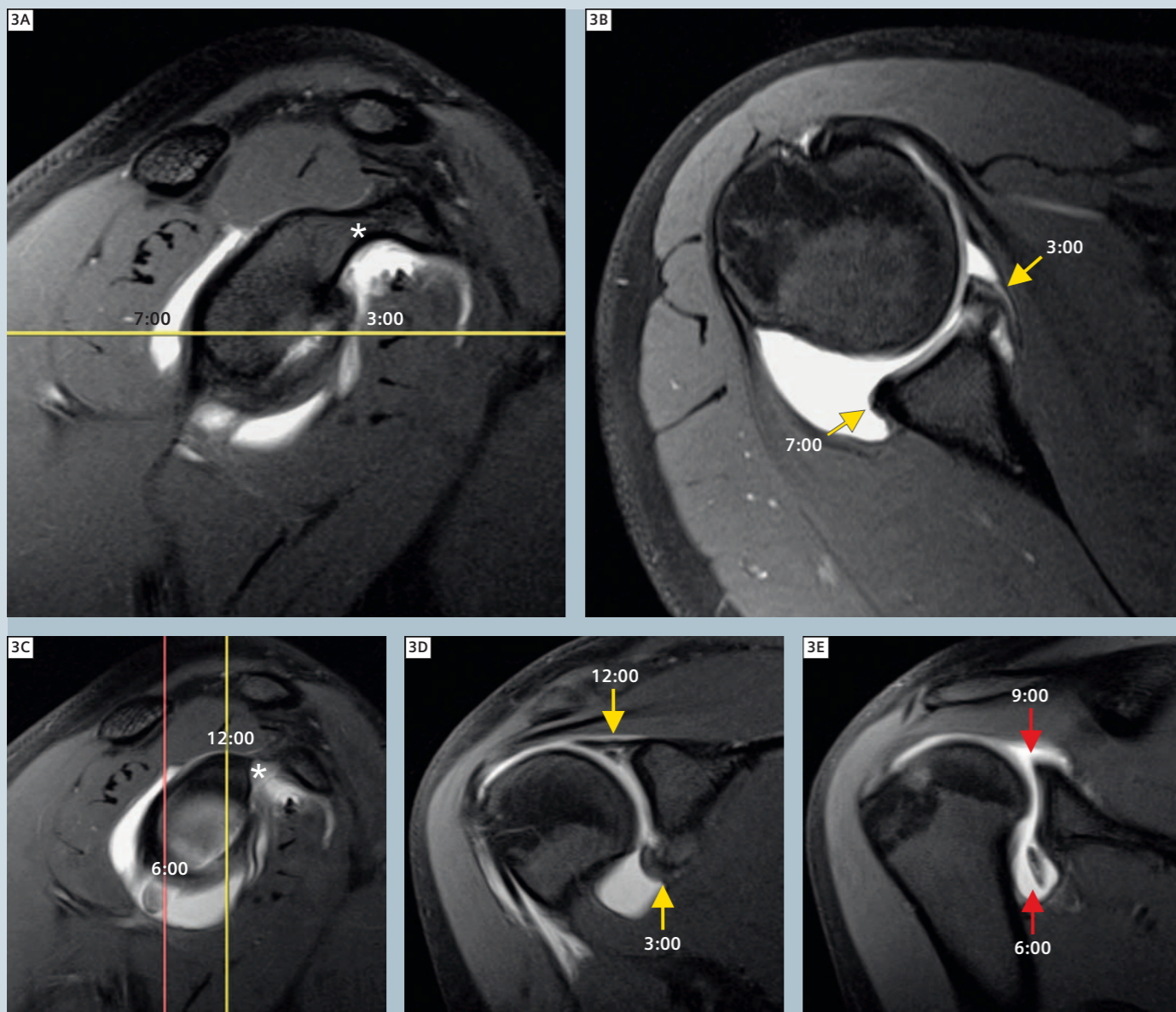
## Discussion

With the shoulder placed in a neutral position, the osseous, tendinous and ligamentous structures supporting the glenohumeral joint are all anatomically oriented with respect to the glenoid clockface. Therefore, in addition to being an ideal presentation of the glenoid labrum, imaging the shoulder orthogo-



2 Using glenoid clockface orientation, proximal biceps tendon (arrows) is imaged along its length in the oblique coronal plane when patient is placed in neutral position.

nal to the glenoid clockface is also an optimal way to evaluate the biceps tendon (Fig. 2), rotator cuff tendons and sources of outlet impingement. When shoulder exams are prescribed without regard to the glenoid clockface, physicians reviewing the exam must rely on scout lines and interactive PACS tools to accurately determine the positions of the glenoid labrum on axial and coronal sequences. By utilizing the glenoid clockface orientation, the labrum is consistently and predictably presented in an orientation familiar to clinicians and radiologists.



**Clinical Cases**

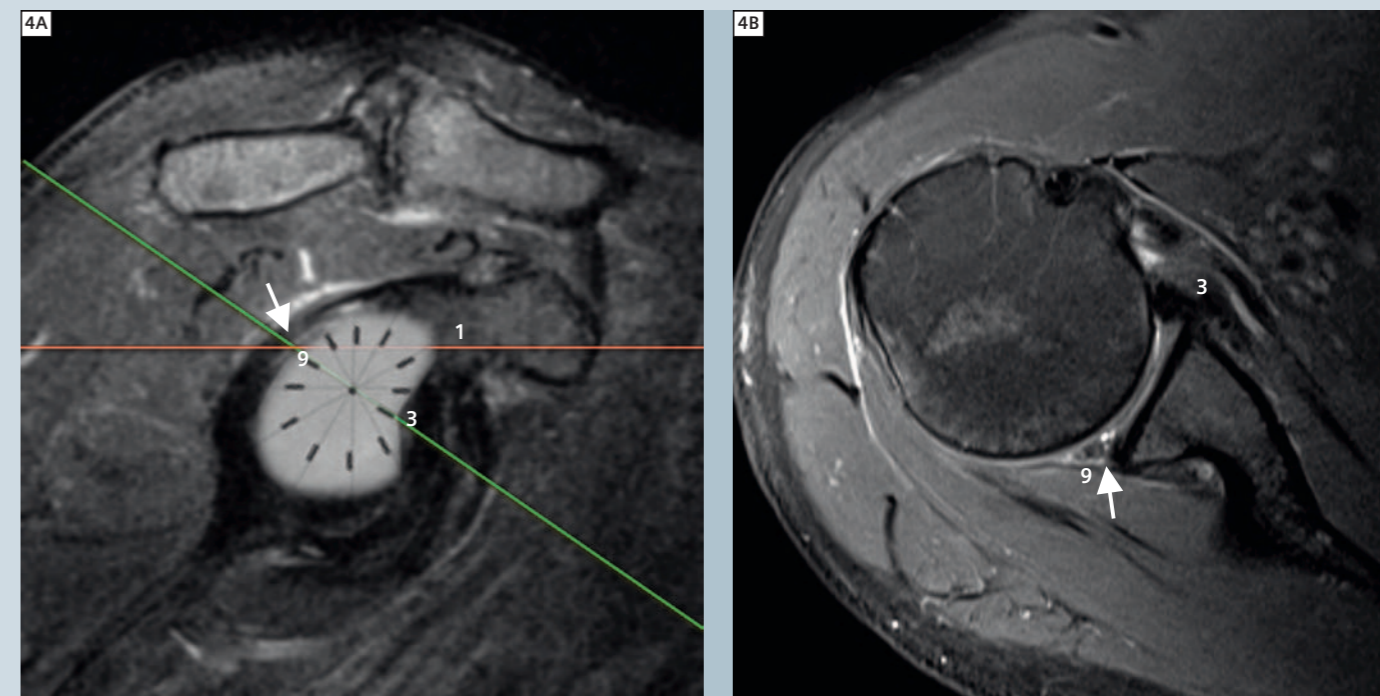
**Case 1: Disadvantages of not using Glenoid Clockface Orientation**

(A) MR Arthrogram of the right shoulder in an 18-year-old volleyball player with superior labral (SLAP) tear and inferiorly displaced tear of anteroinferior glenoid labrum. Straight coronal and axial prescriptions were utilized rather than orienting to the glenoid clockface (asterisk marks the 1:00 position of the acromion). Note how the straight axial prescription (Fig. 3A) results in the 3:00 anterior position

positioned opposite the 7:00 postero-inferior position on axial images (Fig. 3B), which is an unintuitive and unpredictable presentation.

(B) Straight coronal prescription in the same patient unnecessarily complicates identification of labral pathology. Had a glenoid clockface orientation been utilized, the 12:00 superior labral tear would have appeared on the same coronal image as the displaced tear of the 6:00 inferior labrum.

However, since straight prescriptions were used (Fig. 3C), the SLAP tear appears on the same image as the 3:00 anterior position (Fig. 3D) and the inferiorly displaced tear appears on the same image as the 9:00 posterior labral position (Fig. 3E).



**Case 2: Advantages of using Glenoid Clockface Orientation**

38-year-old male with tear (arrows) involving the 9:00 to 11:00 positions of the posterosuperior quadrant of the-glenoid labrum. Utilizing the glenoid clockface orientation on a sagittal image (Fig. 4A, green line), the torn 9:00 posterior labrum is opposite the

3:00 anterior labrum on an axial image (Fig. 4B), which is what one would intuitively expect. Had axials been prescribed without regard to the glenoid clockface, then the 9:00 posterior position would have appeared opposite the 1:00 anterosuperior position (Fig. 4A, red line), which would have resulted in an unintuitive presentation.



Steven D. Needell, M.D.

**Contact**  
 Steven D. Needell, M.D.  
 Director Musculoskeletal Imaging  
 Boca Radiology Group, P.A.  
 951 NW 13th St, Suite 1C  
 Boca Raton, FL 33486  
 USA  
 Phone: +1 561.391.1728  
 Fax: +1 561.447.4316  
 sneedell@bocaradiology.com